



Clinical Images

Peripilar keratin cysts or pseudonits: When nits are not nits!

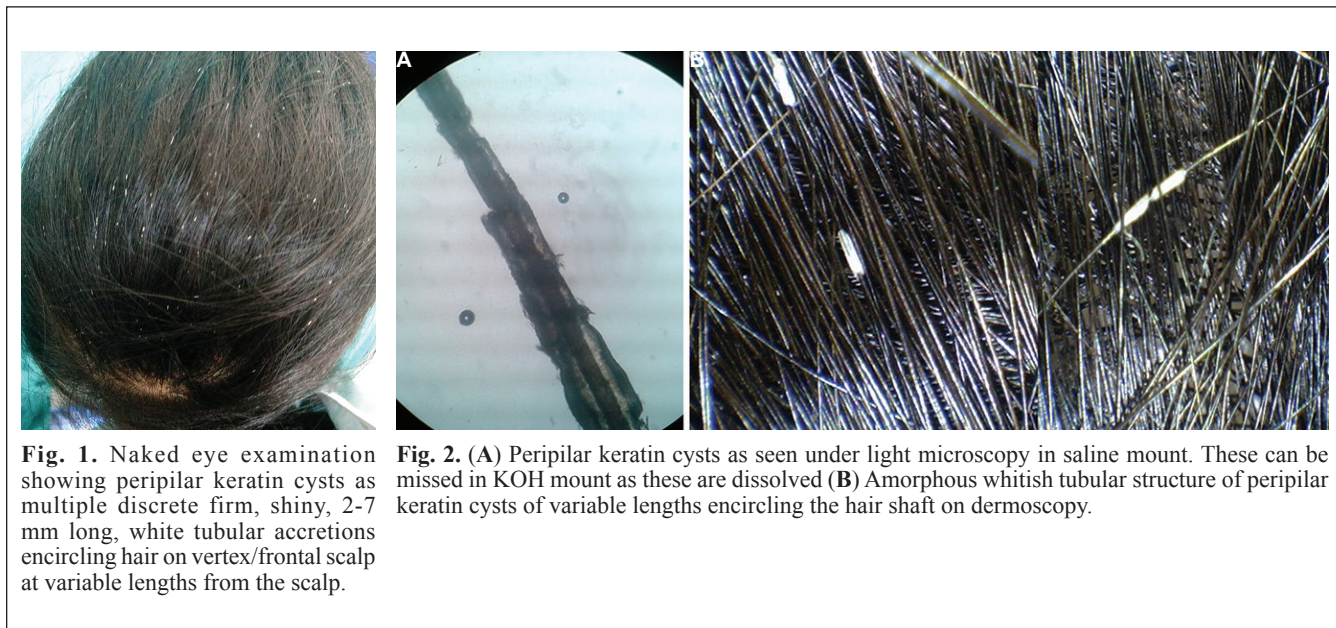


Fig. 1. Naked eye examination showing peripilar keratin cysts as multiple discrete firm, shiny, 2-7 mm long, white tubular accretions encircling hair on vertex/frontal scalp at variable lengths from the scalp.

Fig. 2. (A) Peripilar keratin cysts as seen under light microscopy in saline mount. These can be missed in KOH mount as these are dissolved (B) Amorphous whitish tubular structure of peripilar keratin cysts of variable lengths encircling the hair shaft on dermoscopy.

A 19 yr old girl presented to the Dermatology Outpatient Clinic of Dr. R. P. Government Medical College, Kangra (Tanda), Himachal Pradesh, India, in April 2015, with whitish cylindrical nits-like structures of variable sizes encircling scalp hair shafts (Fig. 1) for the past 5-6 months. Their removal by washing or combing and treatments for pediculosis was unsuccessful. She did not have seborrhoeic dermatitis or pediculosis capitis. KOH mounts showed no fungus. A diagnosis of peripilar keratin cysts was made after light microscopy and dermoscopic examination (Fig. 2). Tretinoin 0.025 per cent solution application overnight, shampooing and combing next morning for two weeks was useful, after that she did not come for follow up.

Pseudonits resembling lice/nits cause significant psychosocial embarrassment in children/adolescents.

These are often idiopathic/primary or secondary to seborrhoeic dermatitis, psoriasis or excessive traction. Treatment with topical retinoic acid (0.025%) solution and keratolytic/tar shampoos and physical removal become imperative to prevent embarrassment, but recurrences are usual.

Ritu Rawat & Vikram K. Mahajan*

Department of Dermatology,
Venereology & Leprosy,
Dr. R. P. Government Medical College,
Kangra, Tanda 176 001,
Himachal Pradesh, India

*For correspondence:
vkm1@rediffmail.com

Received December 30, 2015