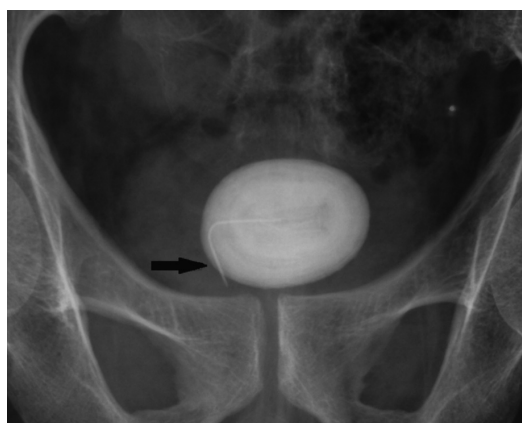




## Clinical Images

### An unusual vesical stone



**Fig. 1.** Pelvic radiograph showing a vesical stone with a foreign body at the centre (arrow).



**Fig. 2.** A vesical stone with a needle (arrow).



**Fig. 3.** A hypodermic needle was found after the stone was fragmented.

A 39 yr old male presented to the department of Urology, North Eastern Indira Gandhi Regional Institute of Health and Medical Sciences, Shillong, India, in October 2014, with poor urinary stream, dysuria and haematuria for three years. Clinical examination was unremarkable. Urine microscopy showed haematuria and leukocyturia. Pelvic radiograph showed a bladder stone with a foreign body at the centre (Fig. 1). On cystolithotomy, a 4 cm × 3 cm stone with a needle (Fig. 2) was removed. When the stone was fragmented, a hypodermic needle was found forming a nidus for the stone (Fig. 3). The patient had an uneventful recovery. He was asymptomatic at three

month follow up. Although he denied it, he possibly inserted the needle through the urethra. His psychiatric evaluation was normal.

**Stephen Lalfakzuala Sailo<sup>1,\*</sup> &  
Laltanpuui Sailo<sup>2</sup>**

Departments of <sup>1</sup>Urology & <sup>2</sup>Anaesthesiology,  
North Eastern Indira Gandhi Regional Institute  
of Health & Medical Sciences, Shillong 793 018,  
Meghalaya, India

*\*For correspondence:*  
stephensailo@gmail.com

Received September 11, 2015