

9 PRECLINICAL REPRODUCTIVE AND GENETIC TOXICOLOGY

9.1 Exposure of Endocrine Disrupter, Bisphenol A in Neonatal Rats: Developmental Effects on Hypothalamus, Pituitary and Testicular axis

Principal Investigator	:	Geeta Vanage
Project Associates	:	S. Chilgunde, P. Patil, Jyoti Kamble, Varsha Padwal, Smita Salian, D. Kumar
Duration	:	2006-2009

The recent finding of high concentration of Bisphenol A (BPA) in male rat fetal serum than female confirmed that BPA can transverse the placental barrier and thus fetuses are at a much higher risk of BPA exposure. As the programming of the Hypothalamus-Pituitary-Testicular (HPT) axis as well as development and differentiation of the testis and reproductive tract occurs during neonatal period in rodents, exposure of BPA in this critical window may exert an adverse effect on reproduction during adulthood. The present study aims to investigate the effect of exposure of neonatal male rats to low doses of BPA (closer to human exposure level, 2.4 g/kg/day) on their fertility and HPT axis during development at cellular and molecular level with following objectives, 1) To identify the Environmentally Relevant Dose (ERD) of BPA that impairs fertility and its correlation to hormonal profile, 2) To study the effect of ERD of BPA on the expression profiles of Androgen Receptor, Estrogen Receptors & their co-activators and co-repressors in the HPT axis at the gene and protein level and 3) To determine the differentially expressed genes in the pre-pubertal and adult testis of control and treated male rats (exposed neonatally to ERD of BPA) by Microarray Approach. Preliminary results demonstrated that exposure of both in neonatal male rats were effective in impairing fertility of male rats during adulthood. Amongst the various doses studied, 2.4 µg dose of BPA was found to be the lowest Environmentally Relevant Dose (ERD) that could impair fertility in males (Annual Report 2005-06, p 205-209). Subsequent studies were performed utilizing 2.4 µg ERD of BPA.

Transient changes in steroid receptors

and their coregulator expression pattern in the developing reproductive tract and HPT axis would lead to permanent impairment in a wide number of receptor responsive genes. Coregulators are ubiquitously expressed however very limited information is available detailing their cellular distribution profile in reproductive tissues like testis, hence present study was undertaken. Coregulators interacting with steroid receptors and playing a significant role in reproductive physiology were selected for further studies. During the reporting year a study was undertaken to study the effect of 2.4 µg dose of BPA on the expression profiles of Androgen Receptor (AR), Estrogen Receptors & their co-activators & co-repressors in the HPT axis at the gene and protein level and the present report describes the effect testes during development.

Protein Expression Studies using Immunohistochemistry

Testicular tissue obtained from set of neonatal animals treated with BPA and vehicle control were sacrificed on PND 15,30,45,60,75,90 and 125 i.e. during development. Immunohistochemical localization for ER (alpha and beta), AR, and Coregulators etc was carried out on testicular tissues during development.

Steroid receptors like Androgen Receptors, Estrogen Receptor Beta (ER β) and Estrogen receptor alpha (ER α) were immunolocalized on rat testicular sections obtained from neonatally exposed BPA (ERD treated) and vehicle control rats. Fig. 142-145 depicts the representative images of AR, ER α and ER β and coregulators respectively. Fig. 146-147 summarizes representative images of Image analysis results for the above proteins.

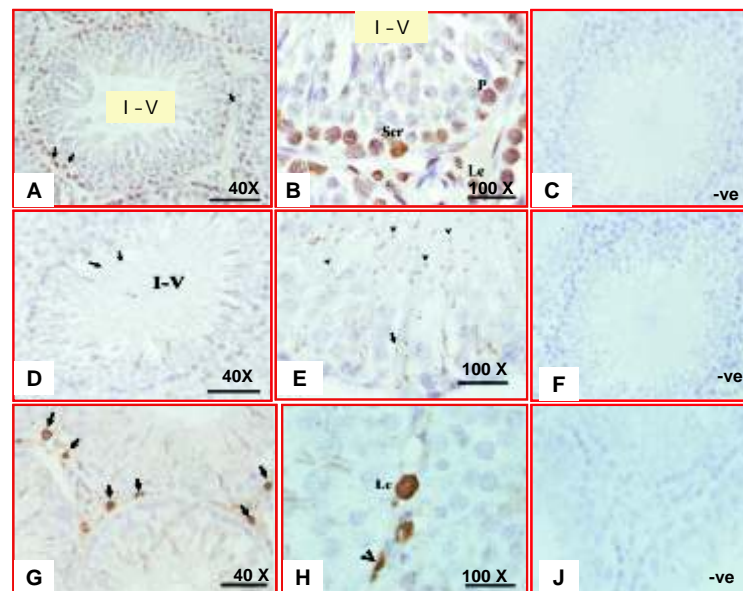


Fig. 142: Immunohistochemical localizations of Androgen Receptor (AR), Estrogen Receptor Beta (ER β) and Estrogen Receptor (ER α) in testicular cross sections of neonatally exposed vehicle control postnatal day (PND) 90 old rats. AR (A, B, and C) was nuclear localized in Ledyig cells (Le), Myoid cells (M) and in Sertoli cells (Ser) in a stage dependent pattern. AR localization in Sertoli cells was maximum in stage VII-VIII seminiferous tubules across all the testes section. Immunohistochemical nuclear localization of ER β (D, E and F) was seen in the Pachytene spermatocytes (P) of the seminiferous tubules and in the intratesticular Leydig cells. Few Leydig cells showed exclusive cytoplasmic and nuclear localization of ER α (G,H and I) and no immunostaining inside the tubules. Panel C shows staining in testes of negative control group incubated with primary antibody preabsorbed with their respective blocking peptides (viz. AR). Panel F (ER β) and I (ER α) shows staining in testes of negative control group incubated with their respective preimmune sera. All sections were counterstained with hematoxylin.

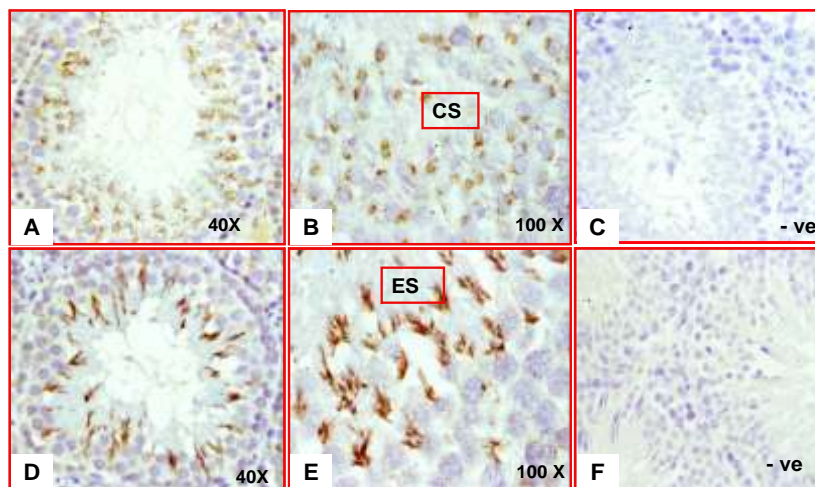


Fig. 143: Immunohistochemical localizations of Steroid Receptor Coactivator 1 (SRC-1), Steroid Receptor Coactivator -3 (SRC-3/p/CIP) and Nuclear Co repressor (NCoR) in testicular cross sections of neonatally exposed vehicle control postnatal day (PND) 90 old rats. SRC-1 (A, B and C) was nuclear localized in Sertoli cells (Ser), Leydig cells (Le) and Pachytene spermatocytes (P) and localization was maximum in stage I-IV seminiferous tubules across all the testes section. SRC-3/p/CIP (D, E and F) staining was seen as cytoplasmic dots within the seminiferous tubules of stages I-IV. The presence of NCoR (G,H and I) was found to be cytoplasmic and nuclear in adult Leydig cells as well as pre-Leydig cells (indicated by arrow head in Panel H). Panel C, F and I shows staining in testes of negative control group incubated with primary antibody preabsorbed with their respective blocking peptides (viz. SRC-1, p/CIP and NCoR). All sections were counterstained with hematoxylin.

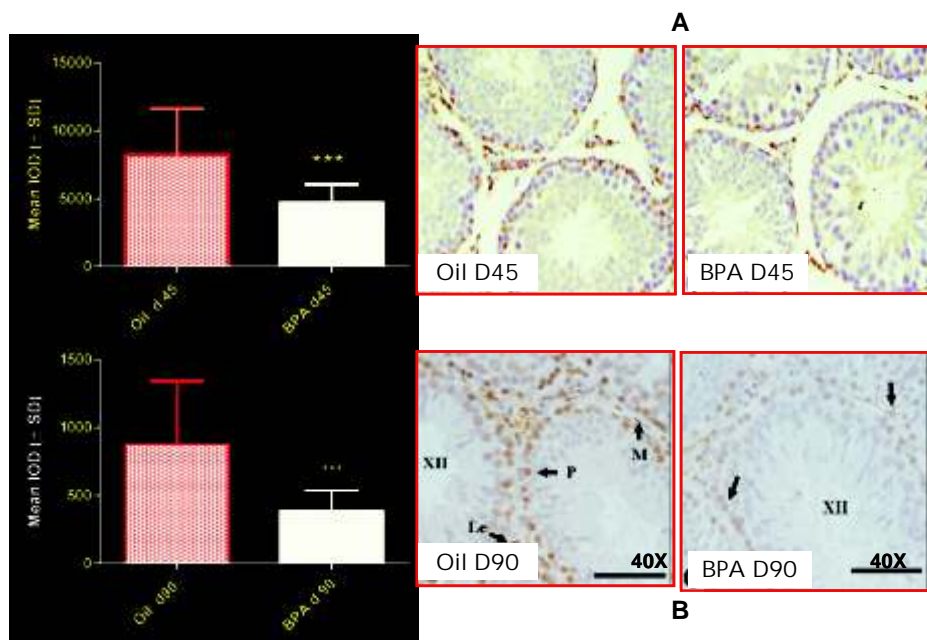


Fig. 144: Immunohistochemical localizations of Steroid Receptor Coactivator 2 (SRC-2/GRIP-1) in the acrosomal region (Elongating Spermatids (ES) and Cap phase spermatids (CS)) in testicular cross sections of neonatally exposed vehicle control postnatal day (PND) 90 old rats. Panel A-C depicts GRIP-1 localization in the Elongating Spermatids (ES) and Panel D-F shows GRIP-1 localization in Cap phase spermatids (CS). Panel C and F shows staining in testes of negative control group incubated with primary antibody preabsorbed with their respective blocking peptides. All sections were counterstained with hematoxylin.

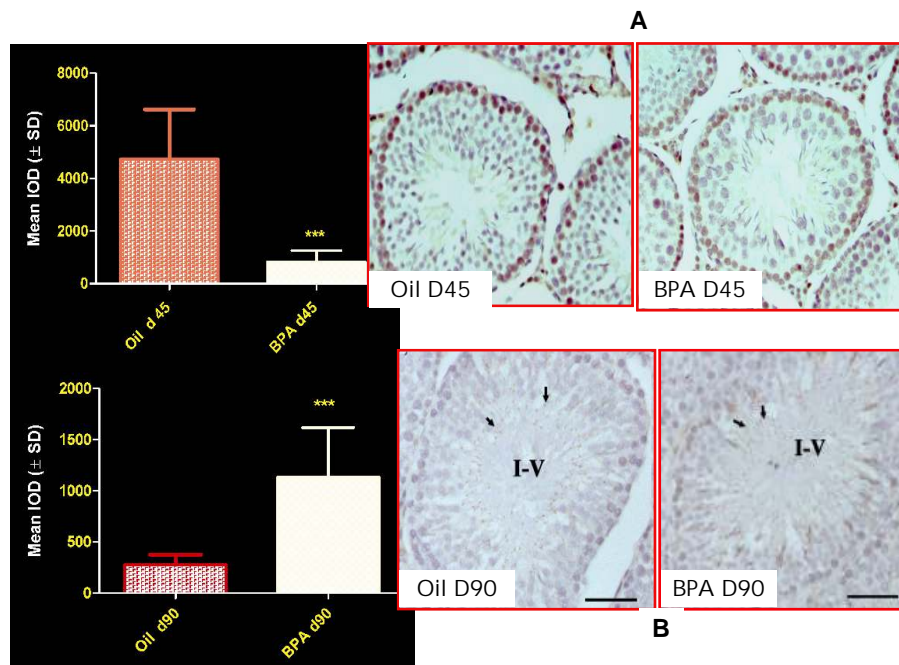


Fig. 145: Image analyses (Mean IOD \pm SD) data of localization of AR (A) and ER (B) in adult rat testicular tissue. Inset Figure A depicts an overall decrease in expression of AR in testicular sections obtained from neonatally exposed BPA treated (2.4 $\mu\text{g}/\text{kg}$ bw) on PND 45 as compared to control Inset Figure B depicts an overall decrease in expression of ER in Stage XII testicular sections of neonatally exposed BPA treated (2.4 $\mu\text{g}/\text{kg}$ bw) in adult PND 90 as compared to control Asterisks indicate significant difference from control (***) $P < 0.0005$.

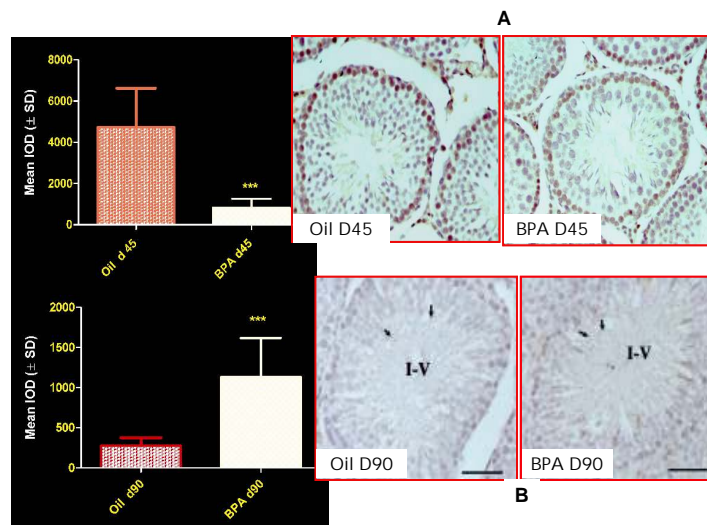


Fig. 146: Image analyses (Mean IOD ± SD) data of localization of SRC-1 (A) and SRC-3/p/CIP (B) in adult rat testicular tissue. Inset Figure A depicts an overall decrease in expression of SRC-1 in testicular sections obtained from neonatally exposed BPA treated (2.4 µg/kg bw) on PND 45 rats as compared to control. Inset Figure B depicts an overall increase in expression of p/CIP in testicular sections obtained from neonatally exposed BPA treated (2.4 µg/kg bw) adult PND 90 rats as compared to control Asterisks indicate significant difference from control (***P* < 0.0005).

Results of Image analyses of testicular steroid receptors (AR, ER and ER) and their coregulators (SRC-1, SRC-2/GRIP-1 and SRC-3/p-CIP) obtained from neonatally exposed BPA treated (2.4 µg/kg bw) males as compared to their respective age controls during development

control (***P* < 0.0005).

Changes in the protein expression pattern of these steroid receptors and their coregulators during development will have significant influence on development of the steroid responsive organs

Table 18: Results of Image analyses of testicular steroid receptors.

	Day 15	Day 30	Day 45	Day 60	Day 75	Day 90
ER alpha	↓	↓***	↓***	↓	↓	↓
ER beta	↓*	↓	↓***	↓***	↓***	↓***
AR	↓	↓	↓	↓***	↓***	↓***
NCoR	↓	—	↓	↓	↓	—
SRC-1	↓	↓	↓***	↓	↓	↓
GRIP-1		↑	↑	↑	↑	↑***
p/CIP			↑	↑	↑***	↑***

(Table 18). Up and down arrows depict an increase and decrease in protein expression and dash indicates no change in protein expression. Asterisks indicate significant difference from

Gene Expression Studies using Real Time PCR
Relative gene expression pattern for steroid receptors (ER , ER and AR) using Real time PCR was performed.




Fig. 147: Graphical representation of changes in gene expression of testicular steroid receptors (AR(A), ER (B) and ER (C)) obtained from neonatally exposed BPA treated(2.4 µg/kg bw) males as compared to their respective age controls during development using real time PCR.

Results of real time analysis of testicular steroid receptors (AR, ER and ER) obtained from neonatally exposed BPA treated (2.4 µg/kg bw) males as compared to their respective age controls during development is as summarized in Table 19. Up and down arrows depict an increase and decrease in protein expression and dash indicates no significant change in the gene

expression.

These results demonstrated that neonatal exposure of male rats to environmentally relevant doses of BPA lead to impairment in expression pattern of steroid receptors and co regulator proteins causing long lasting impacts on their fertility.

Table 19: Results of real time analysis of testicular steroid receptors

	Day 15	Day 30	Day 45	Day 60	Day 75	Day 90
ER alpha	↑	↓	↓	↓	↓	↓
ER beta	↑	↓	↓	—	↓	↓
AR	—	—	↓	↓	—	↓***